



### PATIENT

Sydney Sammies  
Friends

### SPECIES

Canine

### BREED

Shepherd Mix

### SEX

Female Instct

### AGE

20 weeks

### WEIGHT

25.8lbs

### INTERPRETED BY

Maggie Machen Lamy,  
DVM, DACVIM  
(Cardiology)

### IMAGING PERFORMED BY

Loetitia St-Jacques,  
LVT/RVT

### HOSPITAL NAME

Brighton Greens  
Veterinary Hospital

### REFERRING VET

Dr. Janeway

### INVOICE

32279

### DATE

8/9/23

### PRESENTING CLINICAL SIGNS

History: Grade 3/6 heart murmur. Asymptomatic. Assess prior to anesthesia.

### ECHOCARDIOGRAM FINDINGS

2D, m-mode, color flow and doppler imaging is available. Normal mitral valve with no obvious prolapse into the left atrial lumen. No mitral regurgitation with normal left atrial dimension. Normal LV diameter with adequate myocardial function. Normal LV wall thickness. The tricuspid valve appears normal in form and function. No TR. Normal right atrial and ventricular diameter and morphology indicating no overt evidence of pulmonary arterial hypertension. The pulmonic and aortic valves are normal in morphology and mobility. No aortic and mild pulmonic insufficiency. A perimembranous VSD is readily visualized; L-R just below the aortic valve. Max velocity 4.3m/s. Normal aortic and pulmonic outflow velocity. No pericardial or pleural effusion noted. No obvious cardiac tumors.

### CARDIAC CHART

CANINE CARDIAC PARAMETERS	MR VMAX (m/s)	TR VMAX (m/s)	LA/AO (Boon method)	LA/AO (Heart Base; Swe)	FS (%)	EF (%)	EPSS (cm)
<b>NORMAL PARAMETER</b>	4.5-5.5	<2.7	1.3	<1.6	28-40	40-100	<0.6
<b>PATIENT</b>	NA	NA	NM	1.2	35	64	0.4
CANINE CARDIAC PARAMETERS	HR (BPM)	AV VMAX (m/s)	PV MAX (m/s)	BODY WEIGHT (kg)	LA 2D short axis Base view (cm)	LVIDd Avg; 2D and m-mode short axis (cm)	LVIDs Avg; 2D and m-mode short axis (cm)
<b>NORMAL PARAMETER</b>	50-100	0.7-1.7	0.7-1.6	BELOW	BELOW	BELOW	BELOW
<b>PATIENT</b>	NM	1.1	0.7	11.7	2.5	3.9	2.6
*Normal chamber parameters expressed as a mean value (SD)				3	1.27 (5.3)	2.46 (2.46)	1.36 (5.5)
<b>BODY WEIGHT DEPENDENT PARAMETERS</b>				5	1.40 (4.5)	2.74 (5.2)	1.60 (4.7)
*Note: All measurements based upon multi-modal images and methods. An average value is reported.				10	1.50 (3.8)	3.27 (3.5)	2.06 (3.1)
				15	1.83 (2.0)	3.71 (2.4)	2.43 (2.1)
				20	2.02 (1.9)	4.14 (2.2)	2.80 (2.0)
				25	2.18 (2.4)	4.48 (2.9)	3.10 (2.5)
				30	2.33 (3.3)	4.83 (3.9)	3.39 (3.4)
				35	2.48 (4.3)	5.17 (5.0)	3.69 (4.5)
				40	2.62 (5.2)	5.48 (6.1)	3.96 (5.4)
				50	2.88 (7.1)	6.07 (8.3)	4.46 (7.4)

Adapted from June Boon, Veterinary Echocardiography, 1998  
 Rishniw M and Hollis NE, J Vet Intern Med 2000; 14:429-435  
 Hansson et al, Vet Rad and Ultrasound 2002  
 Bonagura et al. Echocardiography: principles of interpretation, Vet Clin North Am 15:1177, 1995

### INTERPRETATION OF THE FINDINGS & FURTHER RECOMMENDATIONS

The cause of the murmur is a perimembranous ventricular septal defect (VSD). The shunt is allowing left to right flow, with no evidence of significant volume overload of the left heart at this time. The size of the defect is relatively small, and typically small shunts do not significantly impact patient QOL or lifespan. It is worth noting, the max velocity is lower than expected with a high velocity shunt. Follow up is recommended to ensure shunt reversal is not developing. There is no cause for the phenomenon to occur and a simple malalignment is most likely. Monitoring is advised for any progressive cardiac dilation or dysfunction lifelong. No concurrent issues such as systolic dysfunction or pulmonary hypertension are noted in this study. The LA and LV both measure normal for this body size, indicating low current risk for complication. No additional



**PATIENT**

Sydney Sammies  
Friends

**SPECIES**

Canine

**BREED**

Shepherd Mix

**SEX**

Female Instct

**AGE**

20 weeks

**WEIGHT**

25.8lbs

**INTERPRETED BY**

Maggie Machen Lamy,  
DVM, DACVIM  
(Cardiology)

**IMAGING PERFORMED BY**

Loetitia St-Jacques,  
LVT/RVT

**HOSPITAL NAME**

Brighton Greens  
Veterinary Hospital

**REFERRING VET**

Dr. Janeway

**INVOICE**

32279

**DATE**

8/9/23

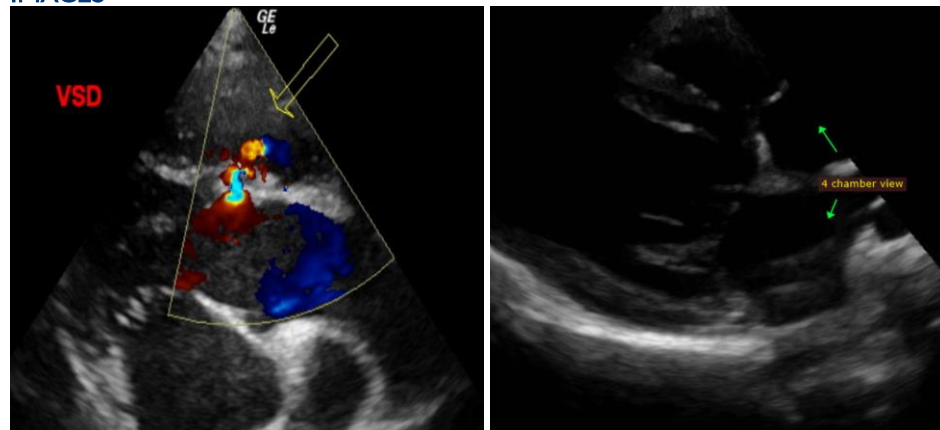
congenital defects are observed; however, it is important to note that ultrasound is not entirely sensitive for small shunts/abnormalities.

No cardiac medications are clearly indicated. Assessment for progressive LA or LV dilation in the future will help predict long term prognosis, which is fair at this time. Omega fatty acid supplementation and mild salt restriction may be of some long-term benefit. Monitor for development of a cough, labored breathing, exercise intolerance or collapse episodes.

Anesthetic risk is considered mild if needed. Cardiac protective drug choices (opioid/benzodiazepine premedication, propofol or alfaxalone induction, isoflurane gas) are recommended. Pre-oxygenate for 5-10 minutes prior to induction. Monitor for arrhythmias, hypotension, and hypoxia both intra and post-operatively and intervene as necessary. Mild IV fluid restriction is recommended to avoid fluid overload. Avoid heart rate stimulating drugs such as atropine unless clinically indicated.

Recommend conservative monitoring with a recheck echocardiogram in 6-12 months to assess for progression. sooner if any development of clinical signs.

**IMAGES**



The information and recommendations provided are based on the images presented by the referring veterinarian. No evaluation can be communicated regarding pathology that was not visible in the image/video clips provided.

Thank you for this referral. This report was generated using transcription software, and minor dictation errors may be present. If the clinical or image interpretation does not parallel your findings or if I can be of any further assistance, please contact me.

**Maggie Machen Lamy, DVM**  
Diplomate of the American College of Veterinary Internal Medicine (Cardiology)  
info@sonopath.com